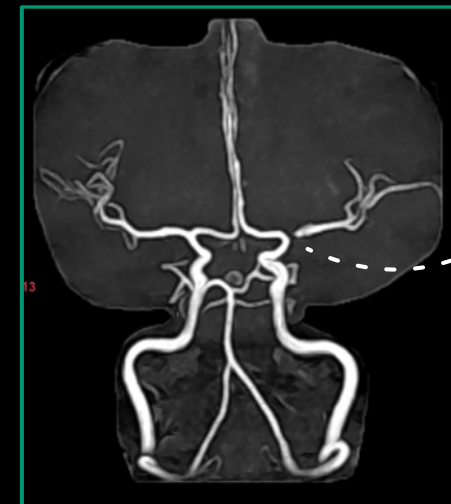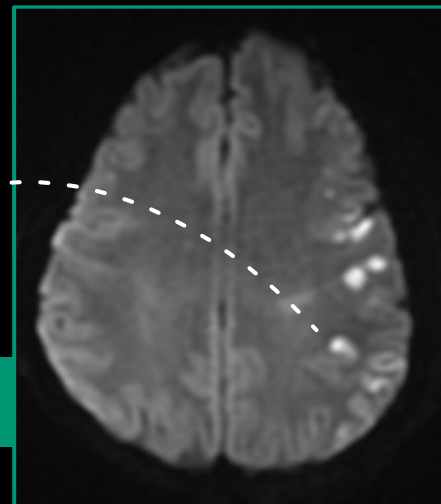


Case 21: MCA Angioplasty

44 YEAR OLD FEMALE

- Had right UL and LL weakness 2 months back, recovered completely while on medications had 2-3 episodes of transient weakness in right UL with slurring dysarthria
- MRI showed multiple left MCA territory infarcts
- MRI angiogram showed left M1 severe stenosis
- She underwent DSA which confirmed left MCA (M1) severe stenosis.
- Patient underwent left MCA angioplasty & stenting
- Discharged without any further episodes & deficits

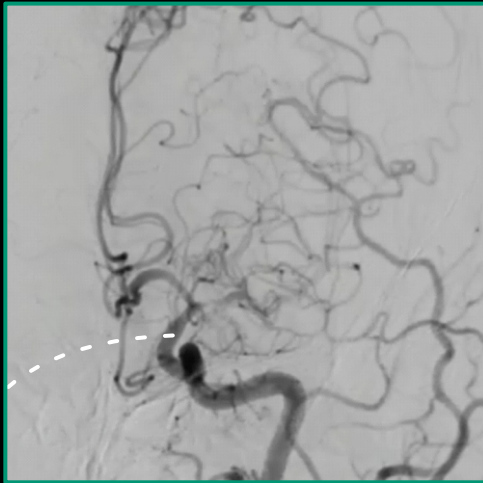
Left M1 severe stenosis



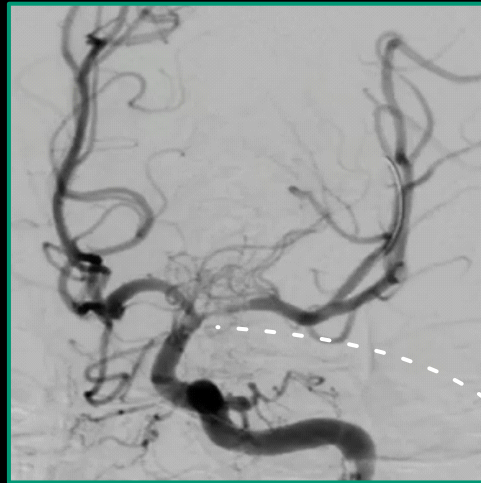
Stent could not be crossed inspite of using buddy wire



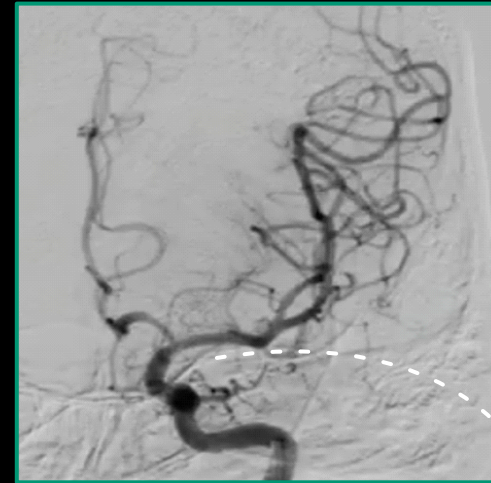
Scan/click to view
Cath Images



Left M1 severe stenosis



Left MCA after
Balloon angioplasty



Left MCA after stenting

